

# Arytenoid cartilage dislocation mimicking bilateral vocal cord paralysis

## A case report

Eun H. Chun, MD, PhD<sup>a</sup>, Hee J. Baik, MD, PhD<sup>a,\*</sup>, Rack K. Chung, MD, PhD<sup>a</sup>, Hun J. Lee, MD<sup>b</sup>, Kwangseob Shin, MD<sup>b</sup>, Jae H. Woo, MD, PhD<sup>a</sup>

### Abstract

**Rationale:** Arytenoid dislocation is very rare and may be misdiagnosed as vocal cord paralysis or a self-limiting sore throat.

**Patient Concerns:** A 70-year-old male (70 kg, 156 cm) was scheduled for transurethral resection of bladder tumors. A McGrath videolaryngoscope, with a basic cuffed Mallinckrodt oral tracheal tube of 7.5 mm internal diameter, was used to successfully intubate his trachea. The duration of surgery was 25 minutes. In the recovery room, he complained of sore throat and dyspnea with inspiratory stridor, which were not resolved after intravenous injection of 10 mg of dexamethasone.

**Diagnoses:** The otolaryngological examination revealed midline fixation of the bilateral vocal folds, suggestive of bilateral arytenoid dislocation or bilateral vocal cord palsy. The latter was ruled out because there was no evidence of recurrent laryngeal nerve injury.

**Interventions:** Under general anesthesia, a closed reduction was performed using laryngoscopic forceps to apply posterolateral pressure on the arytenoid joints on both sides. Only the dislocation of the left cricoarytenoid joint could be easily reduced, whereas reduction of the right joint was not possible.

**Outcomes:** On postoperative day 7, examination with a rigid laryngoscope showed a medially fixed right vocal fold, with full compensation by the left vocal fold. Computed tomography of the neck showed no pathologic findings. Six weeks after surgery, the patient had regained his normal voice with no complications.

**Lessons:** Although arytenoid dislocation is a rare complication, it should be considered even in patients with uncomplicated tracheal intubation. Early diagnosis and the optimal therapeutic approach are critical for restoration of the patient's original vocal cord function.

**Abbreviations:** CT = computed tomography, TURBT = transurethral resection of bladder tumors.

**Keywords:** arytenoid cartilage, endotracheal intubation, general anesthesia

## 1. Introduction

Arytenoid dislocation after tracheal intubation is very rare<sup>[1]</sup> and may be misdiagnosed as vocal cord paralysis or self-limiting hoarseness. However, the early diagnosis and immediate treatment of arytenoid dislocation is critical to reestablish original vocal cord function. We present the case of a patient with left arytenoid dislocation and midline fixation of the bilateral vocal folds. The condition was diagnosed during the

patient's recovery from general anesthesia and was resolved successfully by immediate surgical reduction of the dislocation.

## 2. Case presentation

A 70-year-old male (70 kg, 156 cm) was scheduled for transurethral resection of bladder tumors (TURBT) after a diagnosis of bladder cancer. Previous surgery involved repair of a patellar fracture 42 years earlier. He did not remember whether the anesthesia had been general or regional. Preoperative laboratory tests showed no abnormalities. His Mallampati score was II on preoperative assessment. The patient was not premedicated. In the operating room, his initial blood pressure was 150/102 mmHg, his heart rate was 84 beats/minute, and his peripheral oxygen saturation was 98%. He received 5 L of oxygen/minute through a facemask. Anesthesia was induced with 1.5 mg of midazolam, 100 mg of 1% propofol, 100 µg of fentanyl, and 50 mg of rocuronium, administered intravenously. To attenuate hemodynamic changes because of laryngoscopy, he was also injected intravenously with 100 mg of 1% lidocaine 90 s before endotracheal intubation.

Tracheal intubation with a McGrath videolaryngoscope (Aircraft Medical Ltd, Edinburgh, UK), equipped with a laryngoscope blade #3, was performed successfully using a basic cuffed Mallinckrodt oral tracheal tube of 7.5 mm internal diameter. The Cormack-Lehane grade was I. There was minimal vocal cord movement during tube advancement into the trachea.

Editor: Yung-Song Lin.

The authors declare no conflict of interest.

Supplemental Digital Content is available for this article.

<sup>a</sup> Department of Anesthesiology and Pain Medicine, College of Medicine, Ewha Womans University, <sup>b</sup> Department of Anesthesiology and Pain Medicine, Ewha Womans University Mokdong Hospital, Seoul, Korea.

\* Correspondence: Hee J. Baik, Department of Anesthesiology and Pain Medicine, College of Medicine, Ewha Womans University, 1071 Anyangcheon-ro, Yangcheon-gu, Seoul 07985, Korea (e-mail: baikhj@ewha.ac.kr).

Copyright © 2017 the Author(s). Published by Wolters Kluwer Health, Inc. This is an open access article distributed under the Creative Commons Attribution-NoDerivatives License 4.0, which allows for redistribution, commercial and noncommercial, as long as it is passed along unchanged and in whole, with credit to the author.

Medicine (2017) 96:45(e8514)

Received: 19 February 2017 / Received in final form: 10 September 2017 /

Accepted: 11 October 2017

<http://dx.doi.org/10.1097/MD.00000000000008514>

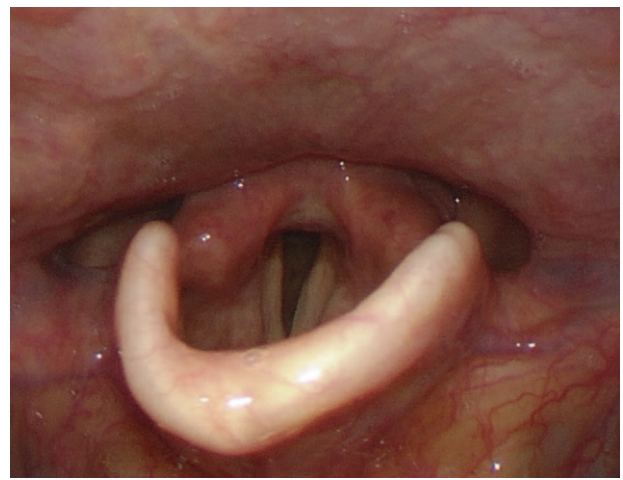


After intubation was confirmed, the cuff was inflated. The patient's lungs were mechanically ventilated with 1.5 L O<sub>2</sub>/minute, 1.5 L N<sub>2</sub>O/minute, and 4 to 6 vol% desflurane. The aneroid manometer (VBM, Sulz, Germany) was connected to the pilot balloon of the endotracheal tube cuff, and the intracuff pressure was maintained below 30 cmH<sub>2</sub>O. The duration of surgery was 25 minutes, after which desflurane was discontinued and the muscle relaxation was reversed by intravenous injection of 0.4 mg of glycopyrrolate and 10 mg of pyridostigmine. The patient was extubated after fully recovering consciousness and respiration. He was transferred to the recovery room without complaints. In the recovery room, his blood pressure was 210/120 mmHg, for which he was treated with 10 mg of labetalol as an intravenous injection. Ten minutes after extubation, he complained of a sore throat and dyspnea and inspiratory stridor developed. He had no difficulty verbalizing his symptoms. His train-of-four ratio, assessed using a TOF-Watch (Organon; Swords Co., Dublin, Ireland), was 100% and he was alert. Suspected laryngeal edema was treated by intravenous injection of 10 mg of dexamethasone. However, after 20 minutes, there was no improvement in his dyspnea or inspiratory stridor. An otolaryngologist was therefore asked to perform a vocal cord examination. The examination revealed midline fixation of the bilateral vocal folds, suggestive of bilateral arytenoid dislocation, or bilateral vocal cord palsy. The latter was ruled out as improbable by the otolaryngologist because there was no reason for bilateral vocal cord palsy because of recurrent laryngeal nerve injury in the setting of a brief urologic procedure. Assuming arytenoid dislocation, we planned a prompt closed reduction of the dislocated arytenoids with the patient under general anesthesia.

Anesthesia was induced using 100 mg of propofol, 100 mg of succinylcholine, and 1.5 mg of midazolam, administered intravenously. Tracheal intubation was easily achieved with a McGrath videolaryngoscope with a laryngoscope blade #3 and a micro-laryngeal tube of 5.0 mm internal diameter. After the intubation was confirmed, the patient was administered 30 mg of rocuronium. Anesthesia was maintained with 1.5 L of O<sub>2</sub>/min, 1.5 L of N<sub>2</sub>O/min, and 1 to 2 vol% sevoflurane. After insertion of the rigid laryngoscope, a closed reduction was performed bilaterally using laryngoscope forceps. However, whereas the left cricoarytenoid joint dislocation was easily reduced, this was not the case for the right cricoarytenoid joint. After the left-side reduction, the endotracheal tube was withdrawn for a few seconds and then immediately reinserted by the surgeon. The laryngoscope view showed complete movement of the left vocal fold but fixation of the right vocal fold (Supplemental Video 1, <http://links.lww.com/MD/B935>). At the end of the operation, sevoflurane was discontinued and muscle relaxation was reversed by intravenous administration of 0.4 mg glycopyrrolate and 10 mg pyridostigmine. The patient was extubated after fully recovering consciousness and respiration. He did not show signs of dyspnea, dysphonia, or stridor.

Under spontaneous breathing, mobility of the vocal fold was confirmed by the otolaryngologist using flexible laryngoscope. In the recovery room, the patient regained his normal voice without throat pain. He was discharged on the second postoperative day without any complications.

On otolaryngologist's follow up examination on postoperative day 7, the rigid laryngoscopic view showed the medially fixed right vocal fold, with full compensation by the left vocal fold (Fig. 1). A computed tomography (CT) scan of the patient's neck was performed by the otolaryngologist to rule out secondary

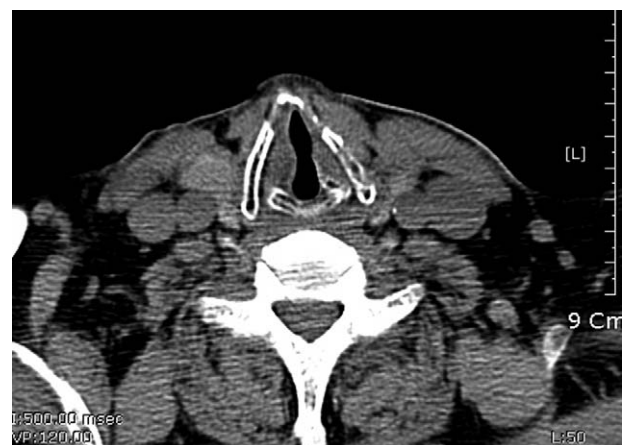

**Figure 1.** The rigid laryngoscopic view showed the medially fixed right vocal fold, with full compensation by the left vocal fold on postoperative day 7.

vocal cord palsy. Based on the absence of pathologic findings on CT scan (Fig. 2), no further examination or treatment was considered. Six weeks after the operation, the patient had regained his normal voice without any complications.

### 3. Discussion

Arytenoid cartilage dislocation is a rare complication with a reported incidence of 0.023% to 0.097%.<sup>[1,2]</sup> The most common etiology is intubation trauma by direct laryngoscopy (77.8%), followed by external neck trauma (17.4%).<sup>[3]</sup> Predisposing factors include diabetes mellitus, chronic renal failure, chronic corticosteroid use, laryngomalacia, and acromegaly, which can weaken the cricoarytenoid joint, and diseases involving the cricoarytenoid joint itself, such as cricoarytenoid arthritis or degenerative changes.<sup>[4,5]</sup> Our patient had no history of any of these predisposing factors. Among the reported cases of intubating injuries, left-sided dislocations account for 55%, right-sided dislocations for 39%, and bilateral dislocations for 4%.<sup>[3]</sup> The left arytenoid is thought to be more vulnerable to subluxation because the laryngoscope is typically held in the left



**Figure 2.** A computed tomography (CT) scan of the patient's neck showed symmetric bilateral vocal fold.



hand of the physician and the endotracheal tube is inserted from the right side.<sup>[4]</sup>

In our patient, a potential cause of laryngeal trauma was that his vocal cord was not fully relaxed when we performed the tracheal intubation. The quality of tracheal intubation is related to laryngeal morbidity; excellent conditions decrease the incidence of postoperative hoarseness and vocal cord sequelae.<sup>[6]</sup> However, it has also been reported that optimal intubation and muscle relaxation conditions do not reduce the rate of symptomatic laryngeal injury after tracheal intubation.<sup>[7]</sup> Thus, the dislocation in our patient may have involved several, as yet unidentified factors in addition to insufficient relaxation.

The arytenoid cartilage articulates with the cricoids through the synovia-lined diarthrodial joint. The anatomy of the cricoarytenoid joint is thought to provide stability to the arytenoid cartilage, preventing its dislocation or subluxation. Wang identified the stabilizing forces contributed by the vocalis ligament, conus elasticus, and anterior capsular ligament, which is resisted posterolateral displacement of the larynx. Anteromedial stability is provided by the cricoarytenoid ligament and posterior capsular ligament.<sup>[8]</sup> Thus, in a normal larynx, significant forces are necessary to disrupt the major support structures of the cricoarytenoid joint and thereby produce subluxation.<sup>[5,8]</sup> In a cadaver study, attempted subluxation of the arytenoids through intubation, extubation, or manual manipulation was unsuccessful in 37 cadaveric larynxes; but rather the hemarthros or fractures of joint, which lead to fixation of the joint surface in an abnormal position, occurred.<sup>[5]</sup> Our patient did not have a difficult airway, as the Cormack-Lehane grade I, and tracheal intubation was performed successfully on the first attempt. Instead, abnormal anatomical conditions may have contributed to the arytenoid dislocation. He had full vocal compensation on postoperative day 7, even though his right vocal fold remained fixed despite closed reduction surgery, and he did not suffer voice change, voice fatigue, or dysphonia, and also there is negative pathologic finding on CT scan; these points suggest that the vocal cord palsy on the right side had occurred well before surgery. In unilateral vocal fold paralysis, the paralyzed arytenoids are passively displaced cranially during phonation, as demonstrated in a study using 3-dimensional CT, and the degree of displacement is proportional to the severity of the palsy.<sup>[9]</sup> In addition, long-standing recurrent laryngeal nerve paralysis leads to structural changes in the articular cartilage<sup>[10]</sup> and decreases the stability of the joint, because of the associated loss of laryngeal muscle tone. This loss of muscle tone leaves the joint susceptible to subluxation.<sup>[3]</sup> Thus, the paralyzed vocal fold may have been susceptible to arytenoid dislocation.

Other causes of arytenoid cartilage dislocation include the use of a laryngeal mask airway<sup>[11]</sup> or the insertion of a transesophageal echocardiography probe.<sup>[12]</sup> Cases of arytenoid cartilage dislocation in patients with apparently uneventful tracheal intubation,<sup>[13,14]</sup> or after a bout of coughing, have also been reported.<sup>[15]</sup> No rigid device, such as a lighted stylet, double lumen tube, or transesophageal echocardiography probe, which might press the arytenoid cartilage downward and outward, was used in our patient during the procedure. Physical force on the tube, a change in the patient's position, or manipulation by the physician during endotracheal suction may also cause laryngeal trauma. However, all of these possible causes of arytenoid dislocation could be ruled out in this patient because of the uneventful procedure and recovery. Although pharyngeal injuries associated with the use of a videolaryngoscope have been described,<sup>[16]</sup> the use of a videolaryngoscope is more likely to

reduce laryngeal trauma by providing a better view of the glottis than achieved with direct laryngoscopy.<sup>[17]</sup> However, unskillful use of a videolaryngoscope may compromise visualization of the glottis, leading to asymmetric forces on the vocal cords, and therefore laryngeal trauma.

Accurate diagnosis is critical to the recovery of normal vocal cord function in patients with arytenoid dislocation. Because the findings of arytenoid dislocation are hoarseness and vocal ligament immobility, which are nonspecific,<sup>[5]</sup> the condition is often misdiagnosed as vocal fold paralysis or postoperative sore throat and hoarseness, which commonly occur after general anesthesia.<sup>[2]</sup> Moreover, it is difficult to differentiate between arytenoid dislocation and vocal fold paralysis on laryngoscopy. However, our patient had very prominent symptoms and signs, including sore throat, chest tightness, and inspiratory stridor, which did not respond to dexamethasone administration. We therefore decided to immediately perform a laryngoscopic examination using a flexible laryngoscope, which revealed bilateral immobility of the vocal folds. The distinctiveness of this case lies in the fact that contralateral arytenoid dislocation occurred in a patient with a pre-existing unilaterally paralyzed vocal cord.

As reduction of an arytenoid dislocation becomes difficult if diagnosis and treatment are delayed, early diagnosis and treatment are recommended. Sataloff<sup>[18]</sup> reported that the average time between injury and surgical treatment was 10 weeks in patients with a favorable outcome, and 29 weeks in patients who did not regain their original voice. Another study showed that early diagnosis followed by closed reduction within 21 days of dislocation is associated with a superior rate of restoration of arytenoid motion.<sup>[19]</sup>

Although spinal anesthesia for TURBT provides excellent intraoperative analgesia, allows earlier determination of hyponatremia due to absorption of bladder irrigation fluids, and reduces the incidence of postoperative venous thrombosis, it cannot prevent adduction of the legs due to stimulation of the obturator nerve by the use of the cautery resectoscope.<sup>[20]</sup> Therefore, we planned general anesthesia with muscle relaxation for this patient to prevent obturator reflex. Spinal anesthesia combined with obturator nerve block may be a good choice for patients with vocal cord disease undergoing TURBT.

#### 4. Conclusions

Although arytenoid dislocation is a rare complication, it should be considered even in patients with straightforward tracheal intubation. The case described herein, of left arytenoid dislocation mimicking bilateral vocal cords paralysis, was diagnosed in a patient who probably had a pre-existing paralyzed right vocal cord. An early diagnosis and optimal therapeutic approach are critical to the restoration of original vocal cord function in patients with arytenoid dislocation.

#### References

- [1] Szigeti CL, Baeuerle JJ, Mongan PD. Arytenoid dislocation with lighted stylet intubation: case report and retrospective review. *Anesth Analg* 1994;78:185–6.
- [2] Yamanaka H, Hayashi Y, Watanabe Y, et al. Prolonged hoarseness and arytenoid cartilage dislocation after tracheal intubation. *Br J Anaesth* 2009;103:452–5.
- [3] Rubin AD, Hawkshaw MJ, Moyer CA, et al. Arytenoid cartilage dislocation: a 20-year experience. *J Voice* 2005;19:687–701.
- [4] Quick CA, Merwin GE. Arytenoid dislocation. *Arch Otolaryngol* 1978;104:267–70.



- [5] Paulsen FP, Rudert HH, Tillmann BN. New insights into the pathomechanism of postintubation arytenoid subluxation. *Anesthesiology* 1999;91:659–66.
- [6] Mencke T, Echternach M, Kleinschmidt S, et al. Laryngeal morbidity and quality of tracheal intubation: a randomized controlled trial. *Anesthesiology* 2003;98:1049–56.
- [7] Bouvet L, Stoian A, Jacquot-Laperriere S, et al. Laryngeal injuries and intubating conditions with or without muscular relaxation: an equivalence study. *Can J Anaesth* 2008;55:674–84.
- [8] Wang RC. Three-dimensional analysis of cricoarytenoid joint motion. *Laryngoscope* 1998;108:1–7.
- [9] Hiramatsu H, Tokashiki R, Nakamura M, et al. Characterization of arytenoid vertical displacement in unilateral vocal fold paralysis by three-dimensional computed tomography. *Eur Arch Otorhinolaryngol* 2009;266:97–104.
- [10] Muller A, Paulsen FP. Impact of vocal cord paralysis on cricoarytenoid joint. *Ann Otol Rhinol Laryngol* 2002;111:896–901.
- [11] Rosenberg MK, Rontal E, Rontal M, et al. Arytenoid cartilage dislocation caused by a laryngeal mask airway treated with chemical splinting. *Anesth Analg* 1996;83:1335–6.
- [12] Niwa Y, Nakae A, Ogawa M, et al. Arytenoid dislocation after cardiac surgery. *Acta Anaesthesiol Scand* 2007;51:1397–400.
- [13] Senoglu N, Oksuz H, Ugur N, et al. Arytenoid dislocation related to an uneventful endotracheal intubation: a case report. *Cases J* 2008;1:251.
- [14] Oh TK, Yun JY, Ryu CH, et al. Arytenoid dislocation after uneventful endotracheal intubation: a case report. *Korean J Anesthesiol* 2016;69:93–6.
- [15] Nerurkar N, Chhapola S. Arytenoid subluxation after a bout of coughing: a rare case. *Am J Otolaryngol* 2012;33:275–8.
- [16] Cooper RM. Complications associated with the use of the GlideScope videolaryngoscope. *Can J Anaesth* 2007;54:54–7.
- [17] Lewis SR, Butler AR, Parker J, et al. Videolaryngoscopy versus direct laryngoscopy for adult patients requiring tracheal intubation. *Cochrane Database Syst Rev* 2016;11:CD011136.
- [18] Sataloff RT, Bough ID Jr, Spiegel JR. Arytenoid dislocation: diagnosis and treatment. *Laryngoscope* 1994;104:1353–61.
- [19] Lee SW, Park KN, Welham NV. Clinical features and surgical outcomes following closed reduction of arytenoid dislocation. *JAMA Otolaryngol Head Neck Surg* 2014;140:1045–50.
- [20] Butterworth JF, Mackey DC, Wasnick JD. *Anesthesia for genitourinary surgery*. Morgan & Mikhail's Clinical Anesthesiology 5th ed. 2013; McGraw-Hill Companies, Inc, New York, NY:676–683.