Polyethylene Wear and Osteolysis After Cementless Total Hip Arthroplasty with Alumina-on-Highly Cross-Linked Polyethylene Bearings in Patients Younger Than Thirty Years of Age

Young-Hoo Kim, MD, Jang-Won Park, MD, Chirag Patel, MD, and Dae-Youn Kim, MD

Investigation performed at The Joint Replacement Center, Ewha Womans University School of Medicine, Seoul, Republic of Korea

Background: We asked whether cementless total hip arthroplasties that made use of alumina-on-highly cross-linked polyethylene bearings would improve hip score and functional activity and reduce the prevalence of polyethylene wear, osteolysis, and aseptic loosening.

Methods: Consecutive primary total hip arthroplasties were performed in fifty patients (a total of sixty hips among thirty-four men and sixteen women) who were younger than thirty years of age. The average age at the time of the index arthroplasty was 28.3 years (range, twenty-one to twenty-nine years). The average follow-up was 10.8 years (range, ten to twelve years). Osteolysis and polyethylene wear rates were evaluated with use of radiography and computed tomography.

Results: The mean Harris hip score, which was 38 points (range, 6 to 45 points) preoperatively, had improved to 95 points (range, 85 to 100 points) at a mean follow-up time of 10.8 years. The mean penetration (and standard error of the mean) of the polyethylene liner was 0.031 ± 0.004 mm per year. No hip had osteolysis or aseptic loosening.

Conclusions: At a minimum of ten years and an average of 10.8 years postoperatively, the current generation of cementless acetabular and femoral components with alumina-on-highly cross-linked polyethylene bearings was functioning well and was not associated with the development of osteolysis in our group of patients younger than thirty years of age. While the long-term prevalence of polyethylene wear and osteolysis remains unknown, the midterm data are promising.

Level of Evidence: Therapeutic Level IV. See Instructions for Authors for a complete description of levels of evidence.

Although total hip arthroplasties have been extremely successful, the survivorship of total hip prostheses in young patients has been limited as a result of aseptic loosening and osteolysis secondary to wear and particulate polyethylene debris[1-4]. Over the last decade, there has been great interest in the development and use of highly cross-linked polyethylene to improve wear performance.

In several studies, the femoral head penetration rate was found to be significantly lower in groups treated with highly cross-linked polyethylene than in groups treated with conventional polyethylene[5-9]. However, the mean follow-up time in each study was less than ten years. Moreover, there is very little clinical or in vivo radiographic evidence supporting the use of highly cross-linked polyethylene in patients who are younger than thirty years of age.

Ceramic bearings offer the advantages of improved lubrication, smoother surface finish, and improved resistance to scratching, and ceramic is composed of biologically inert compounds. As the indications for total hip arthroplasty continue to expand to include younger, more active patients, it has been suggested that because of the superior wear characteristics of ceramic, ceramic bearings may provide an attractive

Disclosure: None of the authors received payments or services, either directly or indirectly (i.e., via his or her institution), from a third party in support of any aspect of this work. None of the authors, or their institution(s), have had any financial relationship, in the thirty-six months prior to submission of this work, with any entity in the biomedical arena that could be perceived to influence or have the potential to influence what is written in this work. Also, no author has had any other relationships, or has engaged in any other activities, that could be perceived to influence or have the potential to influence what is written in this work. The complete **Disclosures of Potential Conflicts of Interest** submitted by authors are always provided with the online version of the article.

alternative to the use of contemporary metal-on-polyethylene bearings[10].

The purpose of the current study was to evaluate the clinical and radiographic outcomes associated with the use of alumina-on-highly cross-linked polyethylene bearings in cementless total hip arthroplasty in patients younger than thirty years of age. In addition, we determined the rate of polyethylene wear and the prevalence of osteolysis in this group of patients.

Materials and Methods

From May 2000 to April 2002, in fifty-seven patients who were younger than thirty years of age, the senior author (Y.-H.K.) performed sixty-seven consecutive cementless total hip arthroplasties in which alumina-on-highly cross-linked polyethylene (Marathon, DePuy, Warsaw, Indiana) bearings were used. The study was approved by our institutional review board, and all patients provided informed consent. Seven patients who moved abroad were lost to follow-up (before two years), leaving fifty patients (sixty hips) in this study.

There were thirty-four men and sixteen women. The average age at the time of the index arthroplasty was 28.3 years (range, twenty-one to twenty-nine years). The average weight of the patients was 68.1 kg (range, 51 to 98 kg). The average height was 165.1 cm (range, 151 to 189 cm) and the average body-mass index was 25.0 kg/m^2 (range, 22.4 to 27.2 kg/m^2). The preoperative diagnosis was developmental dysplastic hip in fourteen patients (28%), childhood septic arthritis sequelae in thirteen (26%), childhood tuberculous arthritis sequelae in ten (20%), multiple epiphyseal dysplasia in nine (18%), Legg-Calvé-Perthes disease in three (6%), and slipped capital femoral epiphysis in one (2%). The average follow-up period was 10.8 years (range, ten to twelve years).

All surgical procedures were performed through a posterolateral surgical approach. A cementless Duraloc 100 or 1200 series acetabular component (DePuy) with a highly cross-linked polyethylene liner (inner diameter, 28 mm) was used in all hips. The average diameter of the cup was 51.2 mm (range, 48 to 54 mm). The average polyethylene thickness was 7.6 mm (range, 6.0 to 8.9 mm). In fifty-two hips (87%), the solid acetabular component was fixed with use of a press-fit technique only; in the remaining eight hips (13%), one or two screws were inserted for fixation of the cups via the screw holes. All patients received an Immediate Postoperative Stability cementless femoral component (IPS; DePuy, Leeds, United Kingdom) with a 28-mm alumina forte ceramic modular femoral head (BIOLOX-forte; CeramTec, Plochingen, Germany). The femoral component was inserted with a press-fit technique. The largest broach that would fill the metaphysis and leave little cancellous bone remaining was used. The IPS femoral component is an anatomic metaphyseal-fitting titanium stem with a polished and tapered distal stem, designed to provide fixation in the metaphysis only and thus avoiding metal-to-bone contact below this point. The proximal 30% of the femoral stem was porous-coated with sintered titanium beads with a mean pore size of 250 μm, to which a hydroxyapatite coating (thickness, 30 μm) was applied.

The patients were allowed to stand on the second postoperative day, and they progressed to full weight-bearing with crutches, as tolerated. They were advised to use crutches for four weeks and then to use a cane, if required, while walking thereafter.

Clinical follow-up was performed at three months, at one year, and yearly thereafter. Harris hip scores[11] and Western Ontario and McMaster Universities Osteoarthritis Index (WOMAC)[12] scores were determined before surgery and at the time of each follow-up examination. Patients subjectively evaluated thigh pain on a 10-point visual analog scale (with 0 indicating no pain and 10 indicating severe pain). The level of activity of the patients after the total hip arthroplasty was assessed with the activity score of the University of California, Los Angeles (UCLA)[13].

Radiographic follow-up was performed at three months, at one year, and yearly thereafter. An anteroposterior radiograph of the pelvis with the patient supine and with both hips in neutral rotation and 0° abduction was made for every patient. Consistent patient positioning was ensured by the use of a frame that was constructed in such a way that it could be placed at the end of a standard x-ray table. Plastic polypropylene orthoses were secured to a plastic back-board through a vertical slot, and a wing nut allowed adjustment for limb length. Rotation and abduction remained constant. Cross-table lateral radiographs were also made of each hip.

Femoral bone type was determined on preoperative radiographs with use of the Dorr classification system[14]. The adequacy of the intramedullary fill by the femoral stem was recorded as satisfactory when the stem filled >80% of the proximal part of the intramedullary canal in the coronal plane and >70% in the sagittal plane, according to a previously described method[15]. The component was considered to be undersized if less of the intramedullary canal was filled in either or both planes.

Definite loosening of the femoral component was defined as progressive axial subsidence of >3 mm or a varus or valgus shift[16]. A femoral component was considered to possibly be loose when there was a complete radiolucent line surrounding the entire porous-coated surface on both the anteroposterior and lateral radiographs[16].

Anteversion of the acetabular component was measured on a true lateral radiograph of the hip as the angle between a horizontal line and a second line marking the plane of the socket. To measure cup abduction, a line that joined the inferior margins of the two acetabular teardrops was drawn on the anteroposterior pelvic radiograph. The intersection of that line, which marked the plane of opening of the socket, determined the angle of abduction.

Definite loosening of the acetabular component was diagnosed when there was a change in the position of the component (>2 mm vertically and/or medially or laterally) or a continuous radiolucent line wider than 2 mm on both the anteroposterior and lateral radiographs[16].

A vertical change in the position of the cup was measured between the inferior margin of the cup and the inferior margin of the ipsilateral teardrop[17], and a horizontal change was measured between the Köhler line (ilioischial line) and the center of the outer shell of the acetabular component[18].

Penetration of the polyethylene liner was measured with AutoCAD 2013 (Autodesk, San Rafael, California) by three observers blinded to the clinical results[18]. The observers made three measurements on each radiograph, and the interobserver error was assessed. A ScanMaker 9600XL flatbed scanner (Microtek, Carson, California) digitized the anteroposterior radiograph of the pelvis as two-dimensional gray-scale arrays of twelve-bit (256-gray level) integers. The scanning resolution was 600 pixels per square inch (psi). Penetration of the head into the liner was determined annually from anteroposterior pelvic radiographs. The amount of penetration on radiographs made three months postoperatively was considered the "zero" position.

The presence and location of areas of osteolysis in the acetabulum and in the femur were recorded in the anteroposterior and lateral radiographs according to the systems of DeLee and Charnley[19] and Gruen et al.[20], respectively. The length and width of osteolytic lesions were measured, and the area was expressed in square centimeters.

Although radiographic evaluation of osteolysis is a direct measure, the current methodology is insensitive and subject to operator error. A more sensitive computed tomography image set provides three-dimensional data, but the beam-hardening artifacts from the prosthesis itself make these images difficult to interpret and use. We developed an algorithm to address the beam-hardening artifacts as well as to measure the volume of osteolytic lesions. We then developed a segmentation algorithm to segment the osteolytic lesions from image data and to measure their volumes. Computed tomographic images were acquired with use of a Siemens scanner (Munich, Germany) with 1-mm collimation, a pitch of 1.5, and a 14 to 22-cm field of view. The raw data were reconstructed for 1-mm slices. The area within 5 cm of the prosthesis-bone interface in all directions was evaluated. The volume of osteolysis was calculated with use of a quantitative imaging system (VirtualScopics, Rochester, New York). Computed tomographic images were acquired for all patients at an average follow-up time of 10.8 years (range, ten to twelve years).

Survivorship analysis was performed with use of the Kaplan-Meier[21] method, with revision for any reason as one end point and revision due to

Fig. 1-A

Fig. 1-B

Fig. 1-C

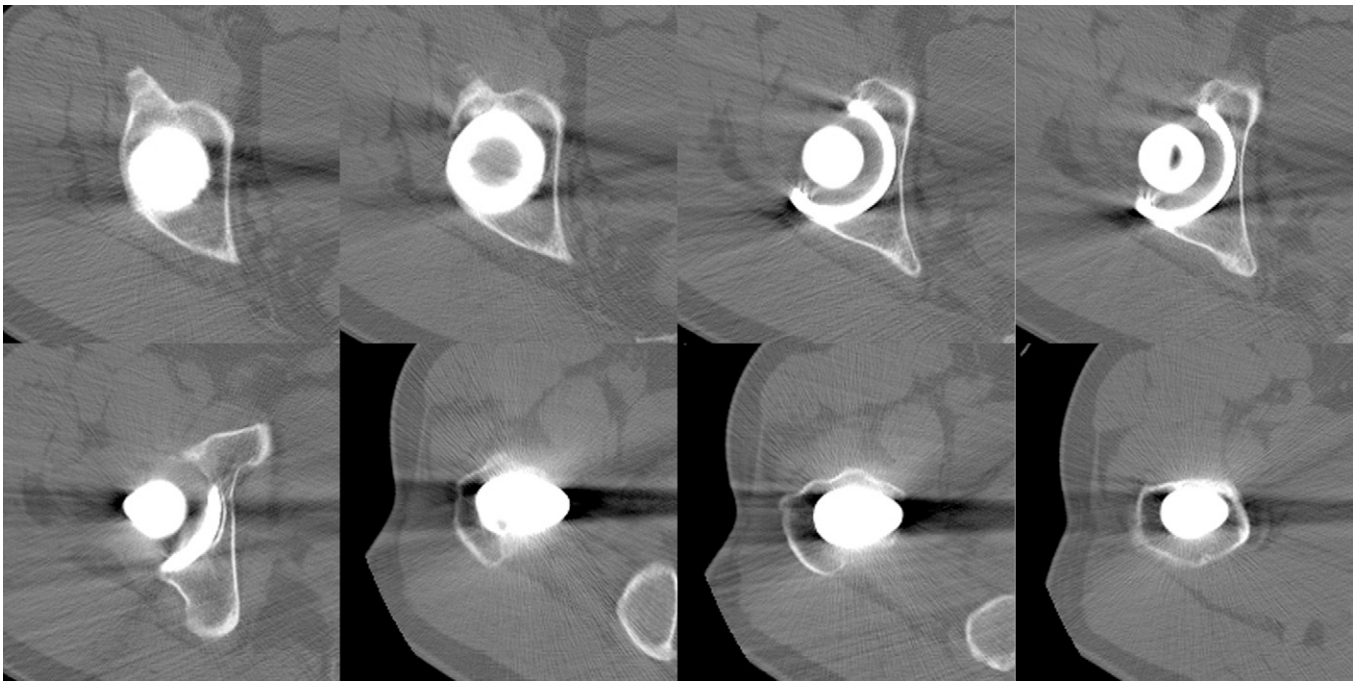

Fig. 1-D

Figs. 1-A through 1-D Radiographic and computed tomographic evaluation of osteolysis of the right hip of a twenty-nine-year-old man with childhood hip sepsis. **Fig. 1-A** Preoperative anteroposterior radiograph of the right hip, showing coxa plana and complete loss of cartilaginous space of right hip joint. **Fig. 1-B** Anteroposterior radiograph of the right hip seven days after surgery, demonstrating that the Duraloc 1200 series cementless acetabular component and IPS femoral component are fixed in a satisfactory position. **Fig. 1-C** Anteroposterior radiograph of the right hip twelve years after surgery, demonstrating that the acetabular and femoral components are fixed in a satisfactory position. Grade-2 bone loss is observed in the calcar region of the hip. There is no evidence of a radiolucent line, polyethylene wear, or osteolysis about the acetabular or the femoral component. **Fig. 1-D** Computed tomographic scans of the right hip twelve years after surgery, revealing no evidence of osteolysis about the acetabular or the femoral component.

mechanical failure (clinical and radiographic evidence of aseptic loosening) at the time of follow-up as the other end point. We determined differences in continuous variances (Harris hip score and range of motion) between preoperative and postoperative results with use of a Student paired t test, and differences in categorical variances (details of functional evaluation and deformity according to the Harris hip score) and limb length between preoperative and postoperative evaluations with use of a chi-square test. Univariate regression analysis was used to evaluate the relationship, if any, between osteolysis and the variables of age, sex, weight, diagnosis, duration of follow-up, and acetabular inclination and anteversion. The level of significance was set at $p < 0.05$.

Source of Funding
There was no external funding source.

Results

At a mean follow-up time of 10.8 years, the mean Harris hip score had improved to 95 points (range, 85 to 100 points) from a score of 38 points (range, 6 to 45 points) preoperatively. The mean WOMAC score had improved to 11 points (range, 8 to 13 points) from a score of 61.8 points (range, 50 to 78 points) preoperatively. Preoperative functional activity (according to the Harris hip scoring system) had improved significantly ($p = 0.001$). The ability to put on footwear, to cut toenails, and to use stairs and public transportation was markedly improved at the time of the last follow-up.

Activity level was improved after the operation. Many patients were quite active following the total hip arthroplasty, despite our admonitions to avoid activities involving high impact. The preoperative UCLA activity score was 3 points (range, 1 to 5 points), which was improved to 6.7 points (range, 5 to 8 points) at the time of the last follow-up.

No hip had aseptic loosening of any acetabular or femoral component. All femoral components had a satisfactory canal-fill on radiographs and all hips had Dorr type-A or type-B bones. The mean inclination and anteversion of the acetabular component was 42.9° (range, 38° to 46°) and 23° (range, 22° to 28°), respectively. All acetabular and femoral components were fixed by bone ingrowth. Calcar rounding off was observed in all hips. No hip had ceramic femoral head fracture. No hip had a squeaking or clicking sound.

The mean total amount (and standard error of the mean) of highly cross-linked polyethylene linear penetration was 0.337 ± 0.315 mm, and the mean annual penetration rate was 0.031 ± 0.004 mm per year. Normal accuracy of measurement of this system was 0.001 mm. The chance-corrected kappa coefficient that was calculated to determine interobserver agreement of hip scoring and wear measurement was between 0.78 and 0.85. We noted increased penetration during the first postoperative year, suggesting the bedding-in period. At a mean follow-up time of 10.8 years, two hips were outliers for the so-called osteolysis threshold of 0.10 mm per year[22-25], with the remaining fifty-eight liners having a penetration rate below this level. In the two hips that were outliers for the osteolysis threshold, there was no evidence of acetabular or femoral osteolysis. With the numbers available, univariate regression analysis showed that age, sex, weight, activity of patients, cup inclination, or cup anteversion had no influence on polyethylene liner penetration.

Radiographs and computed tomographic scans (Fig. 1) demonstrated that no acetabular or femoral osteolysis was detected in any hip at the time of the last follow-up.

One hip (2%) dislocated five days postoperatively and was treated successfully with a closed reduction and an abduction brace for three months. No further dislocation was observed in this hip. No hip had a revision or aseptic loosening of acetabular and/or femoral components. Kaplan-Meier survival analysis, with revision as the end point for failure, showed that the rate of survival of both the acetabular and femoral components at a mean of 10.8 years was 100% (95% confidence interval, 98 to 100).

Discussion

Survivorship of total hip arthroplasty in young patients is poorer than that seen in older cohorts. Young patients may have acquired hip disease from varied causes, and they tend to have higher activity levels than those of older patients. The majority of patients in our series continued to participate in high-demand activities, including moderate to heavy manual labor. These disease entities and the level of activity did not seem to affect the longevity of fixation of the acetabular and femoral components. We believe several factors were responsible for our good results: improved design (the proximal canal-fitting design of the femoral stem including pronounced lateral flare, anteroposterior buildup, and a short and narrow polished distal end of the stem) and surgical technique for implantation of the cementless stem, the strong trabecular bone in young patients, utilization of an alumina femoral head made of highly cross-linked polyethylene, and a cohort of small and light Korean patients. Results may differ in heavier patients.

Our results are consistent with those from other studies of highly cross-linked polyethylene[5,6,10,24-33]. In one study with a minimum five-year follow-up, the wear rate of the highly cross-linked polyethylene liner was 0.029 mm per year compared with 0.065 mm per year for conventional polythylene[26]. In another study with a minimum seven-year follow-up, the mean steady-state wear rate of highly cross-linked polyethylene was 0.005 mm ± 0.15 mm per year)[5]. McCalden et al.[6] reported that the mean femoral head penetration rate in the first through fifth years in patients treated with the highly cross-linked polyethylene was 0.003 ± 0.027 mm per year. With use of edge-detection techniques at four years, the wear rate for highly cross-linked polyethylene was 0.07 mm per year compared with 0.174 mm per year for conventional polyethylene[27,28]. Bitsch et al.[29] reported that, after a mean follow-up duration of 5.8 years (range, 5.0 to 7.7 years), the mean femoral head penetration was 0.031 mm per year (range, 0.04 to 0.196 mm per year) in hips with a Marathon polyethylene liner (DePuy) and 0.104 mm per year (range, 0.04 to 0.196 mm per year) in hips with an Enduron polyethylene liner (DePuy). Osteolysis was not observed in any of the hips with a Marathon liner. Engh et al.[30] reported a reduction in the mean wear rate for Marathon

liners of 95% (0.01 ± 0.12 mm per year) compared with the mean wear rate of Enduron liners (0.19 ± 0.12 mm per year). Kim et al.[31] observed that the mean polyethylene penetration rate for Marathon liners was 0.05 ± 0.02 mm per year and that no hip had aseptic loosening or osteolysis in young patients with femoral head osteonecrosis. For all but two patients in our study, the penetration rate of Marathon highly cross-linked polyethylene was below the osteolysis threshold (0.1 mm per year). No detectable osteolysis was observed on radiographs or computed tomograms in any hips in our study, as noted with other studies[18,28,31,32].

The first generation of highly cross-linked polyethylene had documented reductions in fatigue, tensile, and toughness properties[27]. In the current series, no hip had a polyethylene liner fracture. We believe that the use of an adequate thickness of acetabular polyethylene liner (thicker than 6.0 mm) and satisfactory positioning of the acetabular component led to an absence of polyethylene liner fracture.

There has been some concern that smaller wear particles are produced with highly cross-linked polyethylene than with conventional polyethylene, leading to a higher functional biological activity[34,35]. However, in our 10.8-year follow-up data, no evidence of acetabular or femoral osteolysis was observed. A longer follow-up is necessary to make conclusions about the biological activity of highly cross-linked polyethylene.

While there is a risk of ceramic femoral head fracture, that risk was low enough to go undetected in our small series and was outweighed by the excellent outcomes in a highly active, young group of patients.

There are some limitations of this study. First, the hip scoring system and the measurement of polyethylene wear are prone to interobserver variability. However, the chance-corrected kappa coefficient that was calculated to determine interobserver agreement of hip scoring and wear measurement was between 0.78 and 0.85. Second, there is some potential for bias because this procedure represents one surgical technique and does not have a control or comparison group. Finally, the follow-up was not long enough to make conclusions regarding the theoretical advantage of alumina-on-highly cross-linked polyethylene bearings. Strengths of this study are completeness and length of follow-up as well as consistency of clinical and radiographic examinations.

In conclusion, the current generation of cementless acetabular and femoral components with alumina-on-highly cross-linked polyethylene bearings has functioned well, with no osteolysis at a ten-year minimum and 10.8-year average follow-up period in our patients younger than thirty years of age. While the long-term prevalence of polyethylene wear and osteolysis remains unknown, the midterm data are promising. ■

Young-Hoo Kim, MD
Jang-Won Park, MD
Chirag Patel, MD
Dae-Youn Kim, MD
The Joint Replacement Center,
Ewha Womans University MokDong Hospital,
911-1, MokDong, Yangcheon-gu,
Seoul, Republic of Korea (158-710).
E-mail address for Y.-H. Kim: younghookim@ewha.ac.kr

References

1. Kim YH, Kook HK, Kim JS. Total hip replacement with a cementless acetabular component and a cemented femoral component in patients younger than fifty years of age. J Bone Joint Surg Am. 2002 May;84(5):770-4.

2. Kim YH, Oh SH, Kim JS, Koo KH. Contemporary total hip arthroplasty with and without cement in patients with osteonecrosis of the femoral head. J Bone Joint Surg Am. 2003 Apr;85(4):675-81.

3. Kim YH, Oh SH, Kim JS. Primary total hip arthroplasty with a second-generation cementless total hip prosthesis in patients younger than fifty years of age. J Bone Joint Surg Am. 2003 Jan;85(1):109-14.

4. Kim YH. Cementless total hip arthroplasty with a close proximal fit and short tapered distal stem (third-generation) prosthesis. J Arthroplasty. 2002 Oct;17(7):841-50.

5. Thomas GER, Simpson DJ, Mehmood S, Taylor A, McLardy-Smith P, Gill HS, Murray DW, Glyn-Jones S. The seven-year wear of highly cross-linked polyethylene in total hip arthroplasty: a double-blind, randomized controlled trial using radiostereometric analysis. J Bone Joint Surg Am. 2011 Apr 20;93(8):716-22.

6. McCalden RW, MacDonald SJ, Rorabeck CH, Bourne RB, Chess DG, Charron KD. Wear rate of highly cross-linked polyethylene in total hip arthroplasty. A randomized controlled trial. J Bone Joint Surg Am. 2009 Apr;91(4):773-82.

7. Calvert GT, Devane PA, Fielden J, Adams K, Horne JG. A double-blind, prospective, randomized controlled trial comparing highly cross-linked and conventional polyethylene in primary total hip arthroplasty. J Arthroplasty. 2009 Jun;24(4):505-10.

8. Bragdon CR, Kwon YM, Geller JA, Greene ME, Freiberg AA, Harris WH, Malchau H. Minimum 6-year followup of highly cross-linked polyethylene in THA. Clin Orthop Relat Res. 2007 Dec;465:122-7.

9. Digas G, Kärrholm J, Thanner J, Malchau H, Herberts P. The Otto Aufranc Award. Highly cross-linked polyethylene in total hip arthroplasty: randomized evaluation of penetration rate in cemented and uncemented sockets using radiostereometric analysis. Clin Orthop Relat Res. 2004 Dec;(429):6-16.

10. Urban JA, Garvin KL, Boese CK, Bryson L, Pedersen DR, Callaghan JJ, Miller RK. Ceramic-on-polyethylene bearing surfaces in total hip arthroplasty. Seventeen to twenty-one-year results. J Bone Joint Surg Am. 2001 Nov;83(11):1688-94.

11. Harris WH. Traumatic arthritis of the hip after dislocation and acetabular fractures: treatment by mold arthroplasty. An end-result study using a new method of result evaluation. J Bone Joint Surg Am. 1969 Jun;51(4):737-55.

12. Bellamy N, Buchanan WW, Goldsmith CH, Campbell J, Stitt LW. Validation study of WOMAC: a health status instrument for measuring clinically important patient relevant outcomes to antirheumatic drug therapy in patients with osteoarthritis of the hip or knee. J Rheumatol. 1988 Dec;15(12):1833-40.

13. Zahiri CA, Schmalzried TP, Szuszczewicz ES, Amstutz HC. Assessing activity in joint replacement patients. J Arthroplasty. 1998 Dec;13(8):890-5.

14. Dorr LD. Total hip replacement using APR system. Tech Orthop. 1986;1:22-34.

15. Kim YH, Kim VE. Uncemented porous-coated anatomic total hip replacement. Results at six years in a consecutive series. J Bone Joint Surg Br. 1993 Jan;75(1):6-13.

16. Kim YH, Kim JS, Oh SH, Kim JM. Comparison of porous-coated titanium femoral stems with and without hydroxyapatite coating. J Bone Joint Surg Am. 2003 Sep;85(9):1682-8.

17. Sutherland CJ, Wilde AH, Borden LS, Marks KE. A ten-year follow-up of one hundred consecutive Müller curved-stem total hip-replacement arthroplasties. J Bone Joint Surg Am. 1982 Sep;64(7):970-82.

18. Kim YH, Kim JS, Cho SH. A comparison of polyethylene wear in hips with cobalt-chrome or zirconia heads. A prospective, randomised study. J Bone Joint Surg Br. 2001 Jul;83(5):742-50.

19. DeLee JG, Charnley J. Radiological demarcation of cemented sockets in total hip replacement. Clin Orthop Relat Res. 1976 Nov-Dec;(121):20-32.

20. Gruen TA, McNeice GM, Amstutz HC. ''Modes of failure'' of cemented stem-type femoral components: a radiographic analysis of loosening. Clin Orthop Relat Res. 1979 Jun;(141):17-27.

21. Kaplan EL, Meier P. Nonparametric estimation from incomplete observation. J Am Stat Assoc. 1958;53(282):457-81.

22. Dumbleton JH, Manley MT, Edidin AA. A literature review of the association between wear rate and osteolysis in total hip arthroplasty. J Arthroplasty. 2002 Aug;17(5):649-61.

23. Leung SB, Egawa H, Stepniewski A, Beykirch S, Engh CA Jr, Engh CA Sr. Incidence and volume of pelvic osteolysis at early follow-up with highly cross-linked and noncross-linked polyethylene. J Arthroplasty. 2007 Sep;22(6)(Suppl 2):134-9.

24. Garvin KL, Hartman CW, Mangla J, Murdoch N, Martell JM. Wear analysis in THA utilizing oxidized zirconium and crosslinked polyethylene. Clin Orthop Relat Res. 2009 Jan;467(1):141-5.

25. Kim YH, Kim JS, Choi YW, Kwon OR. Intermediate results of simultaneous alumina-on-alumina bearing and alumina-on-highly cross-linked polyethylene bearing total hip arthroplasties. J Arthroplasty. 2009 Sep;24(6):885-91.

26. Dorr LD, Wan Z, Shahrdar C, Sirianni L, Boutary M, Yun A. Clinical performance of a Durasul highly cross-linked polyethylene acetabular liner for total hip arthroplasty at five years. J Bone Joint Surg Am. 2005 Aug;87(8):1816-21.

27. Bradford L, Baker D, Ries MD, Pruitt LA. Fatigue crack propagation resistance of highly crosslinked polyethylene. Clin Orthop Relat Res. 2004 Dec;(429):68-72.

28. Manning DW, Chiang PP, Martell JM, Galante JO, Harris WH. In vivo comparative wear study of traditional and highly cross-linked polyethylene in total hip arthroplasty. J Arthroplasty. 2005 Oct;20(7):880-6.

29. Bitsch RG, Loidolt T, Heisel C, Ball S, Schmalzried TP. Reduction of osteolysis with use of Marathon cross-linked polyethylene. A concise follow-up, at a minimum of five years, of a previous report. J Bone Joint Surg Am. 2008 Jul;90(7):1487-91.

30. Engh CA Jr, Stepniewski AS, Ginn SD, Beykirch SE, Sychterz-Terefenko CJ, Hopper RH Jr, Engh CA. A randomized prospective evaluation of outcomes after total hip arthroplasty using cross-linked marathon and non-cross-linked Enduron polyethylene liners. J Arthroplasty. 2006 Sep;21(6)(Suppl 2):17-25.

31. Kim YH, Choi YW, Kim JS. Cementless total hip arthroplasty with alumina-on-highly cross-linked polyethylene bearing in young patients with femoral head osteonecrosis. J Arthroplasty. 2011 Feb;26(2):218-23.

32. Dowd JE, Sychterz CJ, Young AM, Engh CA. Characterization of long-term femoral-head-penetration rates. Association with and prediction of osteolysis. J Bone Joint Surg Am. 2000 Aug;82(8):1102-7.

33. Wan Z, Dorr LD. Natural history of femoral focal osteolysis with proximal ingrowth smooth stem implant. J Arthroplasty. 1996 Sep;11(6):718-25.

34. Endo M, Tipper JL, Barton DC, Stone MH, Ingham E, Fisher J. Comparison of wear, wear debris and functional biological activity of moderately crosslinked and non-crosslinked polyethylenes in hip prostheses. Proc Inst Mech Eng H. 2002;216(2):111-22.

35. Fisher J, McEwen HM, Tipper JL, Galvin AL, Ingram J, Kamali A, Stone MH, Ingham E. Wear, debris, and biologic activity of cross-linked polyethylene in the knee: benefits and potential concerns. Clin Orthop Relat Res. 2004 Nov;(428):114-9.